
FAO: Dr. Heaney, re: M Jones MRI Head, 06/03/2103

Michael Jones [REDACTED]

26 September 2013 at 10:46

Reply-To: [REDACTED]

To: jill.rayfield@uclh.nhs.uk

Hospital No: 40840180

Dear Ms. Rayfield,

Following our telephone conversation this morning, I write to draw attention to concerns I have over the results of my MRI Head scan conducted at NHNN on 6 March this year, since I obtained a copy of that scan from the Medical Records Dept. of the hospital. As I have not yet had any direct consultation over these scan results from Dr. Heaney, I hope that I can present these concerns by email, which might pre-empt the need for a consultation.

I have attached copies of details from 3 images from the scan, which seem to reveal evidence of a self-evident anomaly. The three images are images 51, 52, & 53, from the 128-image sequence (sagittal sections) located in the top folder named 'AAH Scout', in the scan explorer window which opens when running the scan application.

The images show the presence of a rigid box-like structure (or structures), apparently of non-biological origin, approximately 1cm square, and situated behind the back of my throat, close to the brain-stem. The object(s) are identifiable to a depth of 3-4mm in the scan sequence (consecutive images in the sequence being 1.6mm apart). There may be further anomalies in other images from this series.

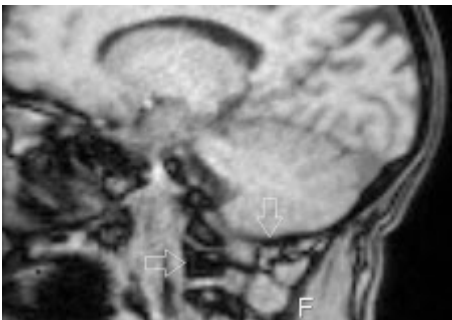
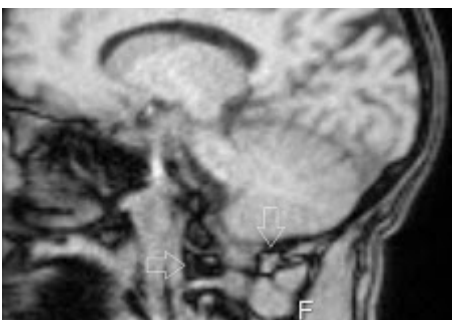
Dr. Heaney had made no reference to this anomaly in his letter to my GP of 18/03/2013. I understand that the evidence I refer to raises some highly controversial medical and legal issues, and that the anomaly is not one that fits into any recognised medical definition or diagnostic category - reasons which may have made it difficult or impossible to report it explicitly to my GP, or to myself, at the time.

It is important for me to be able to establish the *fact* of this anomaly, regardless of there being any satisfactory medical explanation for it; and therefore I am dependent Dr. Heaney's opinion for corroboration.

I am happy to continue this discussion by email, for the time being.

Best wishes,

Michael Jones

3 attachments**R21.6_51.jpg**
63K**R20.0_52.jpg**
63K**R18.4_53.jpg**

64K

